



Ultrasound for point-of-care sputum-free tuberculosis detection: Building collaborative standardized image-banks

Véronique Suttels,^{a,b,*} Prudence Wachinou,^a Jacques Du Toit,^c Noémie Boillat-Blanco,^{b,#} and Mary-Anne Hartley^{d,#}

^aNational Teaching Hospital for Tuberculosis and Respiratory Diseases (CNHU-PPC), Cotonou, Benin

^bService of Infectious diseases, Lausanne University Hospital and University of Lausanne, 1011, Lausanne, Switzerland

^cMRC/Wits Rural Public Health and Health Transitions Research Unit (Agincourt), Faculty of Health Sciences, University of the Witwatersrand, Johannesburg, South Africa

^dIntelligent Global Health Research Group, Swiss Institute of Technology (EPFL), 1015 Lausanne, Switzerland

We thank Nathavitharana and colleagues for their insightful review on sputum-free tuberculosis (TB) diagnostics and its challenges where point-of-care ultrasound is proposed as a likely triage tool.¹ We would like to complement their review with our experience in lung ultrasound (LUS) to motivate the collaborative standardized acquisition of large-scale image banks as a global resource for computer-assisted diagnostics (CAD). Expert LUS interpretation already has an excellent sensitivity for the detection of consolidations, subcentimeter nodules and pleural effusions in patients presenting with acute dyspnea.² Six previous studies on LUS accuracy for TB detection show interesting results but leave us with insufficient evidence due to small sample sizes, imperfect reference standards and lack of standardization of image acquisition protocols and interpretation.³ Considering its sensitivity for the detection of subcentimeter subpleural nodules and small consolidations, we hypothesize a high negative predictive value for TB and possibly more potential when assessed by artificial intelligence (AI), which could make POCUS-CAD a suitable triage tool.

To ensure that such algorithms have an equitable distribution of predictive performance across populations and are reactive to fluctuating epidemiology, it is essential that they are trained on representative populations in various epidemiological settings. Standardization of image quality and its metadata ensures interoperability-at-source. For metadata, it is important to clearly report clinical inclusion criteria as well as presenting symptoms, history and sputum based GeneXpert diagnosis. For image data, we propose a standardized 14-point

sliding-scan protocol (Figure 1) with 4 apical sites. Further, a Focused Assessment with Sonography for HIV-associated TB (FASH plus) is a valuable addition to provide clinical nuance to biomarkers in this high-risk population.^{4,5}

We launched an international prospective cohort study in Sub-Saharan Africa to evaluate the diagnostic performance of LUS for lower respiratory tract infections (Triage Ultrasound in TB-endemic Regions: TrUST).¹ It incorporates a standardized training program and seeks to develop AI-powered CAD for the prediction of TB. Interested stakeholders are invited to contact the authors to join the TrUST study or its training program.

Contributors

VS was responsible for writing the first original draft and made figure 1

PW analyzed the original article by Nathavitharana and colleagues and conceptualized the letter JJD reviewed and commented on the first draft

NBB reviewed and finalized the second draft and conceptualized figure 1

MAH reviewed and finalized the second draft and conceptualized the idea of collaborative standardized image banks

Declaration of interests

All authors have nothing to disclose.

DOI of original article: <http://dx.doi.org/10.1016/j.ebiom.2022.103939>

*Corresponding author.

E-mail address: veronique.suttels@outlook.com (V. Suttels).

© 2022 The Author(s). Published by Elsevier B.V. This is an open access article under the CC BY-NC-ND license (<http://creativecommons.org/licenses/by-nc-nd/4.0/>)

Equal contribution.

¹ Link to clinicaltrials.gov following.

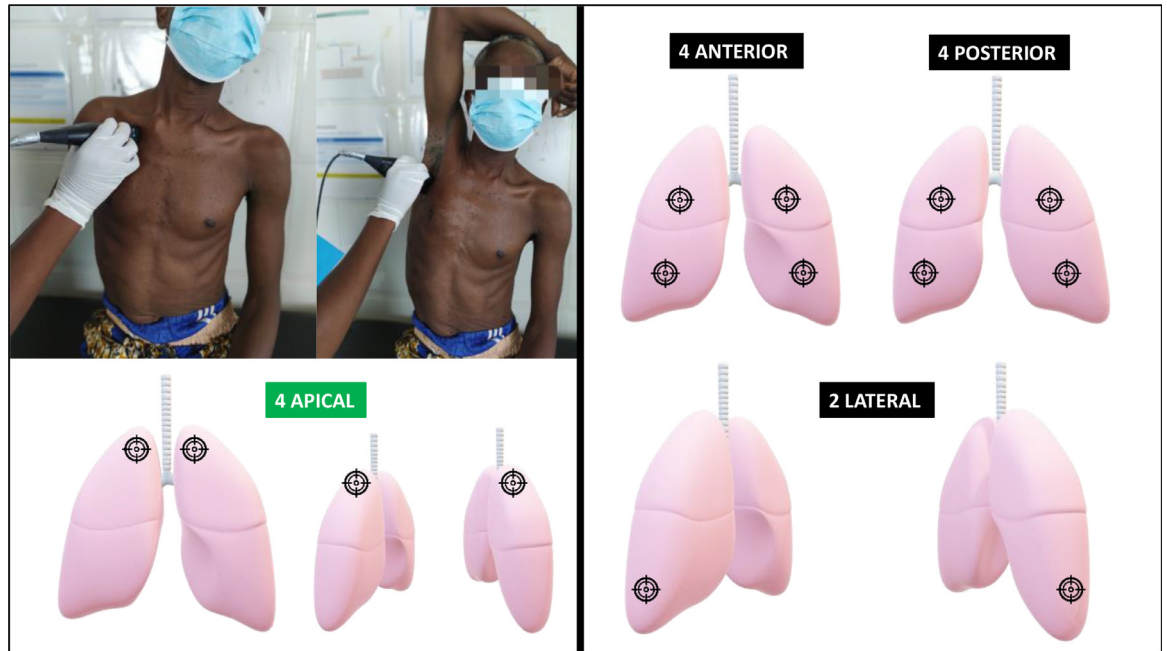


Figure 1. For research purposes, we propose a 14-point sliding-scan protocol for lung ultrasound in TB endemic regions, adding 2 views of each apex in addition to the standard 10-point protocol (sub-clavicular and latero-superior view). Of note, the probe should not be lifted between points but rather slide from point to point to ensure a complete scan. Still images and videos should be taken at each point and labelled according to position. To ensure utility in AI-CAD, images should strictly have no hard coded labels revealing the diagnosis (e.g. arrows pointing to pathologies or text) and should only be used if associated metadata (inclusion criteria, age, sex, geography, healthcare level, presenting symptoms, history and method of TB diagnosis) are provided.

Supplementary materials

Supplementary material associated with this article can be found in the online version at [doi:10.1016/j.ebiom.2022.104078](https://doi.org/10.1016/j.ebiom.2022.104078).

References

- 1 Nathavitharana RR, Garcia-Basteiro AL, Ruhwald M, Cobelens F, Theron G. Reimagining the status quo: How close are we to rapid sputum-free tuberculosis diagnostics for all? *eBioMedicine*. 2022 103939.
- 2 Qaseem A, Etzeandia-Ikobaltzeta I, Mustafa RA, et al. Appropriate Use of Point-of-Care Ultrasonography in Patients With Acute Dys-

pnea in Emergency Department or Inpatient Settings: A Clinical Guideline From the American College of Physicians. *Ann Intern Med*. 2021;174(7):985-993.

- 3 Bigio J, Kohli M, Klinton JS, et al. Diagnostic accuracy of point-of-care ultrasound for pulmonary tuberculosis: A systematic review. *PLoS One*. 2021;16(5):e0251236.
- 4 Heller T, Wallrauch C, Goblirsch S, Brunetti E. Focused assessment with sonography for HIV-associated tuberculosis (FASH): a short protocol and a pictorial review. *Crit Ultrasound J*. 2012;4(1):21.
- 5 Van Hoving DJ, Kenge AP, Maartens G, Meintjes G. Point-of-Care Ultrasound Predictors for the Diagnosis of Tuberculosis in HIV-Positive Patients Presenting to an Emergency Center. *J Acquir Immune Defic Syndr*. 2020;83(4):415-423.